



ISSN: 0976-3031

Available Online at <http://www.recentscientific.com>

International Journal of Recent Scientific Research
Vol. 5, Issue, 6, pp. 1192-1197, June, 2014

**International Journal
of Recent Scientific
Research**

RESEARCH ARTICLE

ASPARAGUS RACEMOSUS ROOTS AMELIORATES ACETAMINOPHEN INDUCED HEPATOTOXICITY IN RATS: AN EXPERIMENTAL, BIOCHEMICAL AND HISTOLOGICAL STUDY

Suchismita Roy^a, Koushik Das^a, Shreya Mandal^a, Shrabani Pradhan^a, Arpita Patra^a, Animesh Samanta^a, Arpita Mandal^a, Sanjoy Kar^b and Dilip Kumar Nandi^{a*}

^aResearch Unit, Developed by Department of Nutrition, Physiology & Microbiology, Raja N. L. Khan Women's College, Midnapore, West Bengal, India

^bDepartment of Botany, Midnapore College, Midnapore, West Bengal, India

Dilip Kumar Nandi, Department of Human Physiology, Nutrition and Microbiology, Raja N L Khan Women's College, Midnapore, Pin-721102, West Bengal, India

ARTICLE INFO

Article History:

Received 14th, May, 2014

Received in revised form 25th, May, 2014

Accepted 13th, June, 2014

Published online 28th, June, 2014

Key word:

Hepatotoxicity, Acetaminophen, *Asparagus racemosus*, Ethanol, Hepatocytes

ABSTRACT

Hepatotoxicity is a major complication of acetaminophen (APAP), widely used analgesic and antipyretic drug. *Asparagus racemosus* (AR) is an Ayurvedic rasayana, which is used for treatment of different diseases by their active compounds. This study incorporates the protective effect of ethanol fraction of AR roots on acetaminophen induced hepatic toxicity and hepatic damage in rats. This fraction displayed significant DPPH free radical scavenging activity against standard ascorbic acid and contains flavonoids and phenolic compounds in high amount. Ethanol fraction of AR was fed to acetaminophen (500mg/kg body weight) induced hepatotoxicity in rats at different doses. Maximum hepatoprotective effect was shown by AR at the dose of 500mg/kg body weight. The marker enzymes of liver toxicity like ALP, AST, ALT, GOT and GPT levels were increased significantly in case of acetaminophen treated group where these enzyme levels significantly resettled to the normal after AR treatment. Also the haematological parameters like haemoglobin and RBC level were significantly increased after treatment of ethanol fraction of AR at 500mg/kg. Acetaminophen injection resulted decrease in liver GSH content which was restored after treatment of AR. Histological pattern of rat liver subjected to acetaminophen hepatotoxicity revealed degenerative changes of liver tissues where after treatment of AR at high dose improvement and rearrangement of liver cells was prominent. These results indicate that the compounds present in the ethanol fraction of AR possesses hepatoprotective activity against acetaminophen induced hepatotoxicity in rats.

© Copy Right, IJRSR, 2010, Academic Journals. All rights reserved.

INTRODUCTION

Acetaminophen (N-acetyl-p-aminophenol; APAP), also known as paracetamol, is the most widely used analgesic and antipyretic medication in the world, which is considered safe at therapeutic dosages. APAP is known to cause hepatic necrosis and renal failure in both humans¹ and animals when administered in overdoses. There are several pathways for acetaminophen metabolism like conjugation with sulfate, glucuronide and metabolism by cytochrome P-450 oxidase enzyme system²⁻³. 90% of ingested dose is metabolized through glucuronidation and sulfation pathway and 5% through cytochrome P-450 oxidase enzyme system⁴⁻⁵. Metabolism by cytochrome P-450 enzyme system produces a metabolite, N-acetyl-p-benzoquinone imine (NAPQI) which is toxic to liver and kidney. In therapeutic dose, this is rendered ineffective by reduced glutathione, an antioxidant compound

in the liver and NAPQI-reduced glutathione is excreted by kidney⁶⁻⁷. As a result of the metabolic conversion of acetaminophen by the microsomal P-450 enzyme system, NAPQI directly reacts with glutathione (GSH) and the depletion of cellular GSH occurs. This allows NAPQI to bind to cellular proteins and initiate lipid peroxidation, leading to hepatic and renal injury. In Indian system of medicine *Asparagus racemosus* (Liliaceae) is an important medicinal plant. Studies on the extracts of AR have revealed a wide range of biological activities. Its pharmacological applications have recently been found to possess a phytoestrogenic effect, an effect on neurodegenerative disorders, as well as antidiarrhoeal⁸, antidyspepsia, adaptogenic, cardioprotective, antibacterial⁹, immunoadjuvant and antitussive effects. Its succulent roots are used as tonic especially during pregnancy, gynaecological disorders like menorrhagia and to promote lactation¹⁰⁻¹¹. The root extracts of *Asparagus racemosus* (AR)

* Corresponding author: Dilip Kumar Nandi

Dilip Kumar Nandi, Department of Human Physiology, Nutrition and Microbiology, Raja N L Khan Women's College, Midnapore, Pin-721102, West Bengal, India

have been employed in form as hydromethanol extracts, against acetaminophen induced uremic rats to reduce nephrotoxicity¹². The therapeutic components present in the root of *Asparagus racemosus* i.e. phytosterols, saponins, polyphenols, flavonoids and ascorbic acid¹³ which may be responsible to reduce the acetaminophen induced hepatic toxicity.

The aim of this study was to evaluate the protective effect of ethanol fraction separated from the hydromethanol extract of AR at different doses for the treatment of acetaminophen induced hepatotoxicity in male albino rats considering hematological, histological and biochemical parameters.

METHODS AND MATERIALS

Drug and Chemicals: Acetaminophen (paracetamol, *N*-acetyl *p*-aminophenol; APAP) was purchased from AshChemie India. It was administered intraperitoneally with saline water. All the chemicals used for preparation of extracts and at the time of Bio chemical tests including ALP, AST, ALT, GOT, GPT kits, other chemicals were collected from Merck Specialities Private Limited Worli, Mumbai, HiMedia Laboratories Pvt. Ltd. Mumbai, India.

Plant materials: The root of *Asparagus racemosus* was collected from Gopali, Indian Institute of Technology, Kharagpur, Paschim Medinipur district of West Bengal. The material was identified by the taxonomist of the Botany Department at the Raja N. L. Khan Women's College, Midnapore. The voucher specimens were deposited in the Department of Botany, Raja N. L. Khan Women's College.

Animal care and selection: The study was conducted on thirty healthy adult male albino rats of Wister strain (supplied from Ghosh animals, Animal foods and animal cages supplier, Kolkata 54) having a body weight of 100 ± 10 g. They were acclimatized to laboratory conditions for two weeks prior to experimentation. The animals were grouped and housed in polyacrylic cages (38 x 23 x10 cm) three rats/cage in a temperature-controlled room (22 ± 2°C) with 12-12 h dark-light cycles (8.00- 20.00 h light, 20.00-8.00 h dark) at a humidity of 50 ± 10 %. They were provided with standard food and water *ad libitum*. Animal care (NIH, 1985) was provided according to the guiding principle for the care and use of animals¹⁴. This experiment was approved by our Institutional Animal Ethical Committee according to the CPCSEA guidelines.

Preparation of ethanol fraction of *Asparagus racemosus* roots:

Ethanol fraction(s) of AR roots was prepared by modified methods in our laboratory¹⁵. Roots of AR were washed and cut into small pieces. The plant parts were shade dried at 37 °C and then crushed in an electrical grinder. A total of 100 g root dust of said plant material was then washed in 400 mL of hexane for 24 h to remove the greasy pigmented non polar materials. Then the hexane was discarded and residue was dissolved in hydromethanol (4:6, v/v) for 2 h in a soxhlet apparatus. Then the extracts were filtered through Whatman No. 1 filter paper and the filtrate was evaporated in a rotary vacuum evaporator. These extracts were used for separation and fractionation of compounds. The hydromethanol extract was then dissolved ethyl acetate for 2 h in a soxhlet apparatus. The extract was filtered through Whatman No. 1 filter paper

and the resulting filtrate was dried in the air. The ethyl acetate extract was dissolved in 250 mL ethanol for 2 h in a soxhlet apparatus. Then it was filtered through Whatman No. 1 filter paper and the resulting filtrate was dried under reduced pressure at 40 °C on a rotary evaporator. Then the ethanol fraction was stored in refrigerator for further study.

Phytochemical investigations of ethanol fraction of AR Antioxidant activity determination by DPPH free radical scavenging assay

DPPH radical scavenging activity of the AR ethanol fraction was measured by DPPH free radical scavenging assay method¹⁶. For this study, different concentrations of sample and ascorbic acid (standard) were prepared with ethanol (Sigma-Aldrich) as the test solutions. About 1 mL of each prepared concentrations were placed into test tubes and 0.5 mL of 1 mmol/L DPPH solution in methanol was added. The test tubes were incubated for 15 min and the absorbance was read at 517 nm. A blank solution consisted of DPPH dissolved in same amount of methanol. The DPPH radical scavenging activity percentage was calculated by using the following formula:

$$\text{DPPH radical scavenging activity (\%)} = \frac{\text{A control} - \text{A AR fraction}}{\text{A control}} \times 100$$

Determination of Total Phenolic Content

Total phenolic contents in the ethanol fraction of AR was determined by the Folin-Ciocalteu reagent method¹⁷. 1 ml of the ethanol fraction (1mg/ml) /standard solution was mixed with 5 ml Folin-Ciocalteu reagent (previously diluted with water 1:10 v/v) and 4 ml (7.5% sodium carbonate) of sodium carbonate. The tubes were vortexed for few seconds and allowed to stand for 30 min at 20°C for color development. Absorbance of samples and standard were measured at 765 nm using spectrophotometer against blank. A typical blank solution contained the solvent used to dissolve the plant extract. The total content of phenolic compounds of plant extracts in gallic acid equivalent (GAE) was calculated using the following equation: $C = (c \times V)/m$ where; C= total content of phenolic compounds, mg/gm plant extract, in GAE, c= concentration of gallic acid established from the calibration curve (mg/ml), V = volume of extract in ml, m = weight of crude plant extract in gm.

Table- 1 Total phenol and flavonoid contents of the ethanol fraction of *Asparagus racemosus*

AR Fraction	Total Phenol Contents (mg/gm, Gallic Acid Equivalent)	Total Flavonoid Contents (mg/gm, Quercetin Equivalent)
Ethanol	165.22	188.33

Table 2 Effect of different dose of ethanol fraction of *Asparagus racemosus* on RBC and hemoglobin level on acetaminophen induced hepatotoxicity in male rats. Group I: control, Group II: Acetaminophen 500mg/kg body Weight, Group III: Acetaminophen 500mg/kg body Weight + AR 125mg/kg body weight, Group IV:

Acetaminophen 500mg/kg body Weight + AR 250mg/kg body weight, Group V: Acetaminophen 500mg/kg body Weight + AR 500mg/kg body weight.

Data are expressed as Mean ± SE (n=6). ANOVA followed by multiple two-tail t-test and data with different superscripts

Groups	RBC /cumm×1000000.	Hemoglobin (g %)
I	7.82±0.53 ^a	7.18±0.25 ^a
II	4.99±0.84 ^d	5.62±0.56 ^c
III	5.02±0.75 ^d	5.59±0.83 ^c
IV	5.50±0.45 ^c	5.71±0.68 ^c
V	6.02±0.86 ^b	7.05±1.05 ^b

(a, b, c, d, e) in a specific vertical column differ from each other significantly ($P < 0.05$).

Table 3 Effect of different dose of ethanol fraction of *Asparagus racemosus* on plasma alkaline phosphatase, alkaline transaminase and aspartate amino transferase on acetaminophen induced Hepatotoxicity in male rats. Group I: control, Group II: Acetaminophen 500mg/kg body Weight, Group III: Acetaminophen 500mg/kg body Weight + AR 125mg/kg body weight, Group IV: Acetaminophen 500mg/kg body Weight + AR 250mg/kg body weight, Group V: Acetaminophen 500mg/kg body Weight + AR 500mg/kg body weight.

Groups	ALP (U/L of plasma)	ALT(U/L of plasma)	AST (U/L of plasma)
I	110.35±4.25 ^c	51.34±4.53 ^d	59.82±4.45 ^c
II	368.46±15.41 ^a	139.88±8.42 ^a	108.35±6.24 ^a
III	372.25±13.62 ^a	136.45±1.06 ^a	96.9±5.75 ^b
IV	371.38±12.45	115.36±1.45 ^b	95.48±0.63 ^b
V	143.23±6.54 ^b	67.01±2.82 ^c	63.75±1.14 ^c

Data are expressed as Mean ± SE (n=6). ANOVA followed by multiple two-tail t-test and data with different superscripts (a, b, c, d, e) in a specific vertical column differ from each other significantly ($P < 0.05$).

Table 4 Effect of different dose of ethanol fraction of *Asparagus racemosus* on plasma GOT and GPT level on acetaminophen induced hepatotoxicity in male rats. Group I: control, Group II: Acetaminophen 500mg/kg body Weight, Group III: Acetaminophen 500mg/kg body Weight + AR 125mg/kg body weight, Group IV: Acetaminophen 500mg/kg body Weight + AR 250mg/kg body weight, Group V: Acetaminophen 500mg/kg body Weight + AR 500mg/kg body weight.

Group	Plasma GOT (U/L of plasma)	Plasma GPT (U/L of plasma)
I	16.4±2.5 ^d	25.4±3.6 ^d
II	64.8±4.4 ^a	72.6±6.7 ^a
III	67.5±5.6 ^a	70.8±4.5 ^a
IV	52.3±6.7 ^b	59.2±5.3 ^b
V	29.9±4.8 ^c	32.1±3.8 ^c

Data are expressed as Mean ± SE (n=6). ANOVA followed by multiple two-tail t-test and data with different superscripts (a, b, c, d, e) in a specific vertical column differ from each other significantly ($P < 0.05$).

Table 5

Effect of different dose of ethanol fraction of *Asparagus racemosus* on liver GSH content on acetaminophen induced hepatotoxicity in male rats. Group I: control, Group II: Acetaminophen 500mg/kg body Weight, Group III: Acetaminophen 500mg/kg body Weight + AR 125mg/kg body weight, Group IV: Acetaminophen 500mg/kg body Weight + AR 250mg/kg body weight, Group V: Acetaminophen 500mg/kg body Weight + AR 500mg/kg body weight.

Data are expressed as Mean ± SE (n=6). ANOVA followed by multiple two-tail t-test and data with different superscripts

Groups	Liver GSH (mg/dl)
I	14.34± 2.11 ^a
II	4.89± 0.58 ^c
III	4.75± 1.33 ^c
IV	6.52± 1.42 ^b
V	13.65± 2.57 ^a

(a, b, c, d, e) in a specific vertical column differ from each other significantly ($P < 0.05$).

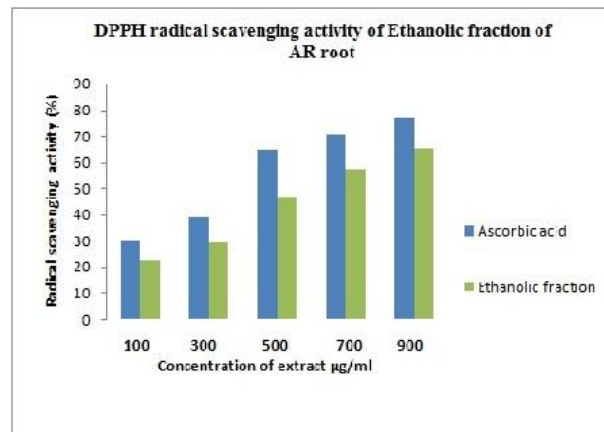


Fig 1 Comparative DPPH radical scavenging activity of Ethanol fraction of *Asparagus racemosus* root and ascorbic acid at different concentrations.

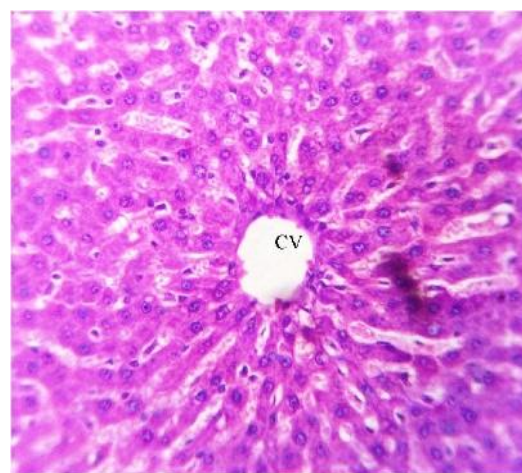

Fig 2 Showing normal histology of liver of control group of rats. Radiating chords of hepatocytes around central vein (CV) indicate well organized histoarchitecture.

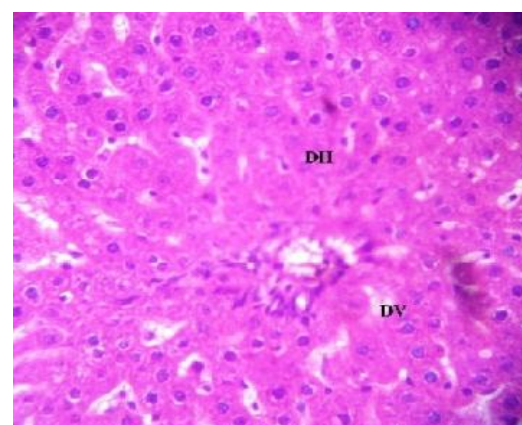


Fig 3 Showing severe disorganization of rat liver after acetaminophen injection of 500mg/kg body weight to Group II rats. Damaged hepatocytes (DH) and damaged blood vessels are seen (DV).

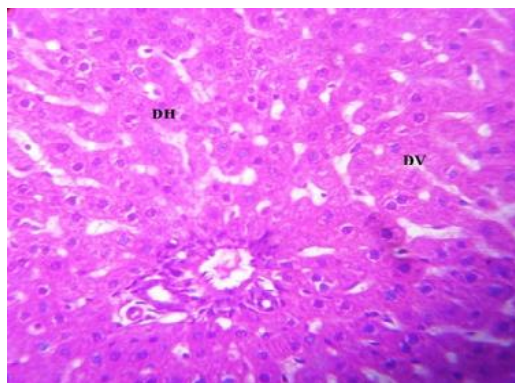


Fig 4 Showing acetaminophen induced hepatotoxic rat liver (500mg/kg body weight) with treatment by AR (125mg/kg) for 10 days to group III rats. Severe infiltration from damaged blood vessel is evident. Liver tissue consists damaged hepatocytes (DH) and damaged blood vessels (DV)

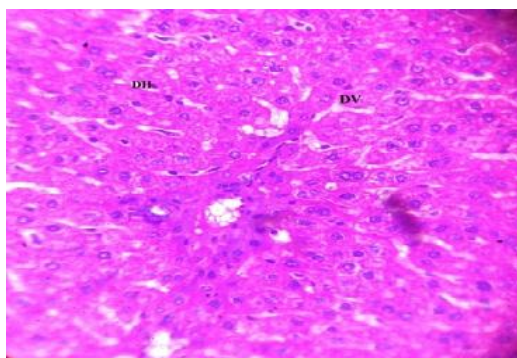


Fig 5 Showing acetaminophen induced hepatotoxic rat liver (500mg/kg body weight) with treatment by AR (250mg/kg) for 10 days to group IV rats. Severe infiltration from damaged blood vessel is evident. Liver tissue consist damaged hepatocytes (DH) and damaged blood vessels (DV).

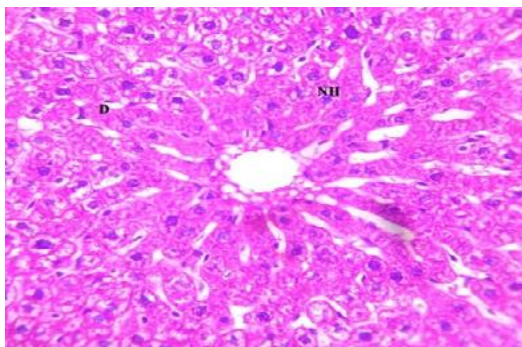


Fig 6 Showing acetaminophen induced hepatotoxic rat liver (500mg/kg body weight) with treatment by AR (500mg/kg) for 10 days to group V rats showing both normal hepatocytes (NH) with a small disorganization (D).

Acute toxicity studies

Acute oral toxicity studies were performed (Ecobichon, 1997) according to Organization of Economic Co-operation and Development¹⁹ guidelines-423 (acute toxic class method). Healthy wistar strain rats (n=6) of either sex selected by random sampling technique were employed in this study. The animals were fasted for 4 h with free access to water only. The ethanol fraction of AR was administered orally at a minimum dose of 5 mg/ kg initially and mortality was observed for 3 days. If mortality was observed in 4/6 or 6/6 animals, then the dose administered was considered as toxic dose. However, if the mortality was observed in only one rat out of six animals then the same dose was repeated again to confirm the toxic effect. If mortality was not observed, the procedure was then

repeated with higher doses, such as 50, 100, 300 and 2000 mg/kg. They were observed continuously for 2h, then occasionally for 4h and finally for overnight mortality. The dose up to 2000 mg/kg was well tolerated without producing any alteration in gross behaviour, signs of toxicity and mortality. Thus all the doses of AR were found to be non-toxic. Three doses (125, 250 and 500 mg/kg) of AR were selected for further studies.

Experimental design

Grouping of animals

Thirty animals were randomly divided into five groups, each consisting of six animals. Group I considered as control receiving normal food and water with 5ml/kg body weight/day de-ionized water intraperitoneally for twenty days. APAP was administered intraperitoneally with de-ionized water at a dose of 500 mg/kg/day²⁰ for 10 days to group II, III, IV and V animals to achieve hepatotoxicity. Group II animals were then considered as hepatotoxicity group and they were kept for next 10 days with normal food and water. On the 11th day, ethanol fraction of AR at the dose of 125mg, 250mg and 500mg/kg body weight/day with 5 ml de-ionized water was then forcefully feed with group III, IV and V animals respectively and continued for next 10 days.

Animals scarification, plasma and organ collection

This experimental design was continued for 20 days. After 20 days, the animals were sacrificed and blood was collected from the aorta for biochemical and haematological analysis, after which the livers were collected for liver glutathione content and histopathological analysis. Blood was centrifuged at 10,000 g for 20min at 4°C and then plasma was collected.

Measurement of hematological and biochemical parameters

Blood was collected in 5 mL syringe into Ethylene Diamine Tetra-acetic Acid (EDTA)-coated sample bottles for analysis of hematological parameters like total RBC by hemocytometer and hemoglobin (Hb) by standard kit method (Merck, Japan). Plasma was separated from whole blood for the estimation of biochemical parameters include alanine aminotransferase (ALT), aspartate aminotransferase (AST), alkaline phosphatase (ALP), GOT and GPT. Hepatic glutathione reductase (GSH) was determined from the liver homogenate²¹.

Histopathological studies

Liver from the experimental rats were fixed in 10% buffered Bouins reagent and were processed for paraffin sectioning. Sections of about 5 mm thickness were stained with haematoxylin and eosin for photomicroscopic observations.

Statistical analysis

Analysis of variance (ANOVA) followed by a multiple two tail test with Bonferroni modification was used for statistical analysis of the collected data. Differences were considered significant when $p < 0.05$.

RESULTS

The percentage inhibition of DPPH radicals by ethanol fraction of AR was shown in Figure 3. In our experiment the antioxidant capacity was compared with the standard ascorbic acid at different concentrations. It may be due to its high phenol and flavonoid contents (Fig- 1).

The quantitative determination of the total phenolic content, expressed as gallic acid equivalent per gram of AR ethanol fraction. Phenol contents of the ethanol fraction of AR was 165.22mg/g. Total flavonoid content of the AR fraction was expressed as Quercetin equivalent per gram of sample showed the content values of 188.3 mg/g shown in table no one.

APAP caused a significant ($P<0.05$) decrease in the levels of hemoglobin and RBC (Table-2) in Group II animals when compared to the normal control group (Group I), resulting in acetaminophen induced hepatotoxicity. Administration of ethanol fraction of AR to group V animals at the dose of 500mg/kg body weight, significantly ($P<0.05$) increased the hemoglobin and RBC levels as compared to the APAP induced group (Group II, Table- 2). Other two lower doses of AR did not restore the hemoglobin and RBC levels as control.

The effect of AR roots at different doses on blood marker enzymes for liver function was shown in table no three and four. The levels of plasma AST, ALT, ALP, GOT and GPT were markedly elevated in APAP treated rats of Group II animals in comparison to control. After treatment of AR at higher dose, there was a significantly ($p<0.05$) decreased levels of these marker enzymes. GSH level in liver tissue also significantly decreased in acetaminophen treated group when compared with control. But after treatment with high dose of AR at 500mg/kg, GSH content in liver tissue was significantly increased (Table-3).

Morphological observations showing normal histology of liver of control group of rats with radiating chords of hepatocytes around central vein indicate well organized histoarchitecture (Fig-2). Figure two showed severe disorganization of rat liver after acetaminophen injection of 500mg/kg body weight. Damaged hepatocytes and blood vessels were seen prominently (Figure 3). By the treatment of AR at the dose of 125mg and 250mg/kg there was also evidence of severe damaged blood vessel and liver tissue consisting of damaged hepatocytes as seen in figure four and five. But after treatment of AR at 500mg/kg the normal hepatocytes are seen as well as slightly affected ones with a small disorganization (Figure 6).

DISCUSSION

Paracetamol is a widely used antipyretic and analgesic drug which is safe in therapeutic doses but can cause fatal hepatic damage in human and animals at higher toxic doses²². Overdose of paracetamol depletes hepatic reduced glutathione (GSH) content so that free NAPQI binds covalently to cellular macromolecules causing acute hepatocellular necrosis. The NAPQI then causes acylation or oxidation of cytosolic and membrane proteins and generation of reactive oxygen species (ROS). Thus the purpose of this detailed investigation was to explore whether or not the ethanol fraction of asparagus racemosus which contains antioxidant, flavonoid and phenolic properties could prevent the hepatic damage caused by acetaminophen, a model hepatotoxicant.

A vital function that blood cells perform, together with the susceptibility of this highly proliferative tissue to intoxication by xenobiotics, makes the hematopoietic system unique as a target organ²³. Certain drugs could also affect blood formation rate and the normal range of hematological parameters²⁴. In the present study, treatment with APAP significantly decreased the hemoglobin and RBC levels. After administration of AR root,

these levels are significantly increased compare to the APAP induced group. However this study shows that the AR roots could contain candidate molecules reversing the hematotoxic effect of acetaminophen, with ensuing improvement of hematopoiesis.

It has been well established that elevated levels of SGOT, SGPT are indicative of cellular leakage and loss of functional integrity of the hepatic cell membranes implying hepatocellular damage. There was a significant ($P<0.05$) increase of these enzyme levels on administration of the ethanol fraction of AR at a dose of 500 mg/kg. The reversal of increased serum enzymes in acetaminophen induced liver damage by the extract may be due to the prevention of the leakage of intracellular enzymes by its membrane stabilizing activity.

ALT and AST are enzymes normally present in the liver, heart, muscles and blood cells. They are basically located within hepatocytes. So when liver cells are damaged or dies, transaminases are released into blood stream, to measure the index of liver injury²⁵. Administration of AR root extract at the dose of 500mg/kg body weight to acetaminophen induced hepatotoxic rats restored the level of ALT, AST and ALP offering the maximum hepato protection with respect to different liver marker enzymes. Thus therapy with *Asparagus racemosus* reversed the activity of transaminases and alkaline phosphatase activities thus restored them towards normal value.

GSH is a major non-protein thiol in living organism, which plays a central role of co-ordinating the body's antioxidant defense process. It is implicated in the cellular defense against xenobiotics and naturally occurring deleterious compounds such as free radicals. Glutathione status is a highly sensitive indicator of cell functionality and viability. Perturbation of GSH status of biological system has been reported to lead to serious consequences²⁵. Decline in GSH in the liver of APAP induced hepatotoxic rats and AR treated at the higher dose of 500mg/kg body weight reveal antioxidant effect. Explanations of the possible mechanism underlying the hepatoprotective properties of drugs include the prevention of GSH depletion and destruction of free radicals²⁶.

Liver is the main organ that is capable of detoxification²⁷. Probably, treatment with *Asparagus racemosus* roots could have enhanced detoxification of acetaminophen thereby maintaining the liver architecture. In the present study the histological pattern of rat liver showed degeneration of hepatic cells (Fig 3) where treatment by AR at 500mg/kg body weight shows an improvement and rearrangement of these cells (fig 6). This is because *Asparagus racemosus* root extract is known to enhance hepatobiliary clearance i.e. improve liver function by detoxification¹³. The protection offered by this fraction could have been due to the presence of flavonoids, antioxidants, phenolic compounds and many other compounds.

CONCLUSION

In conclusion, the overall result suggests that the potential use of the ethanol fraction of *Asparagus racemosus roots* is a novel therapeutically useful hepatoprotective potential which improves hematological derangements associated with repeated dose acetaminophen hepatotoxicity. Although, the active principles were not isolated and their possible

mechanisms of actions were not investigated in the present study, these could constitute areas of future studies. Further studies to characterise the active principles and their mechanisms of action should be conducted to aid the discovery of new therapeutic agents for the treatment of hepatic and renal diseases.

Acknowledgement

The author thanks for financial help provided by Department of Science and Technology (DST), New Delhi as Inspire Fellowship to first author and also acknowledges to UGC-CPE, New Delhi, for providing research fund.

Reference

1. Adeneye AA, Olagunju JA, Benebo AS, Elias SO, Adisa AO, Idowu BO, et al. Nephroprotective effects of the aqueous root extract of *Harungana madagascariensis* [L.]. In acute and repeated dose acetaminophen renal injured rats. *Int J Appl Res in Nat Prod* 2008; 1: 6-14.
2. Barros L, Falcao S, Baptista P, Freire C, Vilas-Boas M, Ferreira IC. Antioxidant activity of *Agaricus* sp. mushrooms by chemical, biochemical and electrochemical assays. *Food Chem* 2008; 111: 61-6.
3. Demiray S, Pintado ME, Castro PML. Evaluation of Phenolic Profiles and Antioxidant Activities of Turkish Medicinal Plants: *Tilia Argentea*, *Crataegi Folium* Leaves and *Polygonum Bistorta* Roots". *World Academy of Science, Engineering and Technology* 2009; 54: 312-7.
4. Fraga C, Leibovitz B, Tappel A. Halogenated compounds as induced of lipid peroxidation in tissue slices. *Free Rad Biol Med* 1987; 3: 119-23.
5. Gamel el-din AM, Mostafa AM, Al-Shabanah O, Al-Bekairi AM, Nagi MN. Protective effect of Arabic gum against acetaminophen induced hepatotoxicity in mice. *Pharmacol Res* 2003; 48: 631-5.
6. Jollow DJ, Mitchell JR, Potter WZ, Davis DC, Gillette JR, Brodie BB. Acetaminophen induced hepatic necrosis. II. Role of covalent binding in vivo. *J Pharmacol Exp Ther* 1973; 187: 195-202.
7. Lee HS, Won NH, Kim KH, Lee HJ, Jun WJ, Lee KW. Antioxidants effects of aqueous extract of *Terminalia chebula* in-vivo and in-vitro. *Biological and Pharmaceutical Bulletin* 2005; 28: 1639-44.
8. Liebert JJ, Matlawska I, Bylka WM, Marek M. Protective effect of *Aquilegia vulgaris* (L) on APAP-induced oxidative stress in rats. *J Ethanopharmacol* 2005; 97: 351-8.
9. Mandal S., Patra A., Samanta A., Roy S., Mandal A., Pradhan S., Das K., Nandi D.K., Analysis of phytochemical profile of *Terminalia arjuna* bark extract with antioxidative and antimicrobial properties. *Asian Pac. J. Trop. Biomed.* 2013; 3: 960-966.
10. Melo DAS, Saciura VC, Poloni JAT, Oliveria CSA, Filho JCFA, Padilha RZ. Evaluation of renal enzymeuria and cellular excretion as a marker of acute nephrotoxicity due to an overdose of acetaminophen in Wistar rats. *Clin Chem Acta* 2006; 373: 88-91.
11. Moron MS, Dsepierre JW, Manerwik KB. Levels of glutathione, glutathione reductase and glutathione-S-transferase activities in rat lung and liver. *Bioche Biophys Acta* 1979; 582: 67-8.
12. Mugford CA, Tarloff JB. The contribution of oxidation and deacetylation to acetaminophen nephrotoxicity in female Sprague-Dawley rats. *Toxicol Lett* 1997; 93: 15-22.
13. Murkies AL, Wilcox G, Davis SR. Phytoestrogens. *J Clin Endocrinol Metab* 1998; 83: 297-303.
14. O'Grady JG. Paracetamol-induced liver failure: prevention and management. *J Hepatol* 1997; 26: 41-6.
15. OECD, Organization of Economic Co-operation and Development guidelines, 423. 2001.
16. Olfert ED, Cross BM, McWilliam AA. Guide to the care and use of experimental animals, second ed. Ottawa, Canada. Canadian Council on Animal Care 1993.
17. Pastore Y. Functional analysis of oxidative stress activated mitogen activated protein kinase cascade in plants. *Proc Natl Acad Sci* 2003; 97: 2940-5.
18. Pradhan S, Mandal S, Roy S, Mandal A, Das K, Nandi DK. Attenuation of uremia by orally feeding alpha-lipoic acid on acetaminophen induced uremic rats. *Saudi Pharmaceutical Journal* 2013; 21: 187-92.
19. Presscott L. Oral or Intravenous N-Acetylcysteine for Acetaminophen poisoning? *Ann. Emerg. Med* 2005; 45: 409-13.
20. Roy S, Das K, Mandal S, Pradhan S, Patra A, Nandi DK. Crude extract from root of *Asparagus racemosus* ameliorates acetaminophen induced uremic rats. *Int J Pharma Sc Res* 2013; 4: 3004- 12.
21. Saxena VK, Chaurasia SA. New isoflavone from the roots of *Asparagus racemosus*. *Fitoterapia* 2001; 72: 307- 9.
22. Slitt AML, Dominick PK, Roberts JC, Cohen SD. Effects of ribose cysteine pretreatment on hepatic and renal Acetaminophen Metabolite formation and glutathione depletion. *Basic Clin Pharmacol Toxicol* 2005; 96: 487-94.
23. Uddin M, Ghufuran MA, Idrees M, Irshad M, Jabeen S, Ahmad W, et al. Antibacterial activity of methanolic root extract of *asparagus racemosus*. *Journal of Public Health and Biological Sciences* 2012; 1: 32-5.
24. Vasudha KC, Nirmal AK, Venkatesh T. Studies on the age dependent changes in serum adenosine deaminase activity and its changes in hepatitis. *Ind J Clin Biochem* 2006; 21: 116-20.
25. Venkatesan N, Thiyagarajan V, Narayanan S, Arul A, Raja S, Kumar SGV, et al. Anti-diarrhoeal potential of *asparagus racemosus* wild root extracts in laboratory animals. *J Pharm Pharm* 2005; 8: 39-46.
26. Visavadiya NP, Narsimhacharya AV. Hypolipidemic and antioxidant activities of *Asparagus racemosus* in hypercholesteromic rats. *Ind J Pharmacol* 2005; 37: 376-80.
27. Wang SY, Jiao H. Correlation of antioxidant capacities to oxygen radical scavenging enzyme activities in blackberry. *J Agr Food Chem* 2000; 48: 5672-6.
